

## Cardiac and Renal Malformations in a Patient with Sepsis and Severe Congenital Neutropenia

Aziz Eghbali\*<sup>1</sup>, MD; Peyman Eshghi<sup>1</sup>, MD; Fatemeh Malek<sup>1</sup>, MD and Nima Rezaei<sup>2,3</sup>, MD, PhD

1. Department of Pediatric Hematology- Oncology, Mofid Children's Hospital, Shahid Beheshti University of Medical Sciences, Tehran, IR Iran
2. Growth and Development Research Center, Tehran University of Medical Sciences, Tehran, Iran
3. Pediatrics Center of Excellence, Children's Medical Center, Tehran, IR Iran

Received: Jun 10, 2009; Final Revision: Oct 15, 2009; Accepted: Oct 21, 2009

### Abstract

**Background:** G6PC3 deficiency is a new neutropenic syndrome, which is characterized by severe persistent neutropenia, early onset infections and additional organ involvement, especially cardiac and urogenital malformations.

**Case Presentation:** In this report, we present the clinical details of a recently known case of severe congenital neutropenia (SCN) with G6PC3 mutation, who experienced the first episode of infections at birth. Repeated absolute neutrophil count of less than 500/ $\mu$ l was detected during work-up of sepsis in the first month of life. SCN was diagnosed and granulocyte colony-stimulating factor (GCSF) administration initiated. Bone marrow examination revealed maturation arrest in myeloid series at promyelocyte-myelocyte stage. Diarrhea, bronchiolitis, and urinary tract infection were other infectious complications, while hydronephrosis, atrial septal defect, and patent ductus arteriosus were other manifestations.

**Conclusion:** Prompt and accurate diagnosis of neutropenic patients and appropriate treatment can prevent further complications and improve the quality of life of the affected patients.

*Iranian Journal of Pediatrics, Volume 20 (Number 2), June 2010, Pages: 225-228*

**Key Words:** Severe congenital neutropenia; G6PC3; Mutation

### Introduction

Severe congenital neutropenia (SCN) is a rare disorder, caused by multiple genetic defects<sup>[1,2,3]</sup>. While persistent severe neutropenia in association of maturation arrest in the myeloid differentiation at promyelocytes-

myelocytes stage are the main characteristics of the disease, early-onset recurrent infections are hallmarks of this immunodeficiency disease<sup>[4,5,6]</sup>.

Patients with SCN usually experience severe bacterial infections in the first year of life, while some patients suffer fungal infections<sup>[7]</sup>.

#### \* Corresponding Author;

Address: Department of Pediatric Hematology- Oncology, Mofid Children's Hospital, Tehran, Iran

E-mail: aziz\_eghbali@yahoo.com

© 2010 by Pediatrics Center of Excellence, Children's Medical Center, Tehran University of Medical Sciences, All rights reserved.

Infections can occur in any organ, especially in mucocutaneous, respiratory and gastrointestinal systems<sup>[2,3,4]</sup>. Although recurrent infections are the most common manifestations of the disease, neurological disorders are recently reported in some SCN patients, who had specific homologous mutations within antiapoptotic HCLS1-associated protein X1 (HAX1) gene<sup>[8,9,10]</sup>.

Cardiac and urogenital malformations as well as increased venous marking have very recently been reported in a group of SCN patients with homologous mutations within glucose-6-phosphatase catalytic subunit 3 (G6PC3) gene<sup>[11]</sup>.

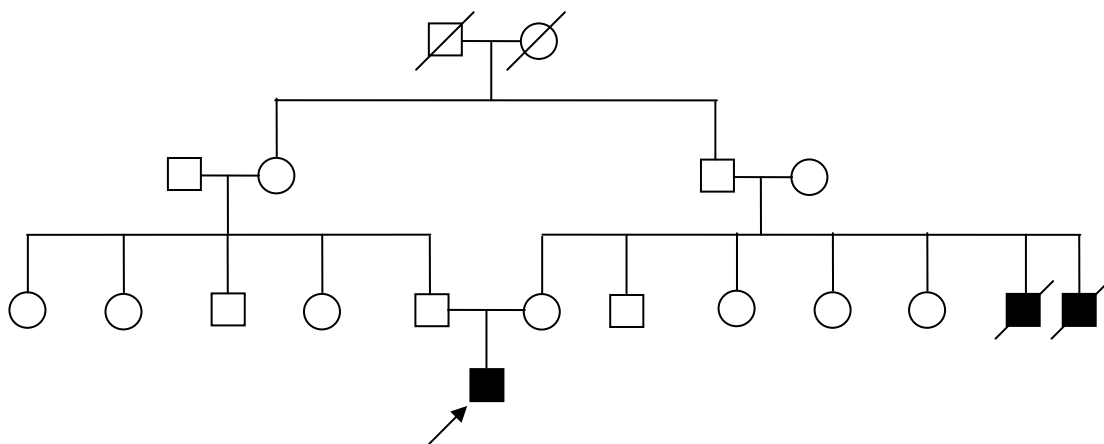
In this report, we present a G6PC3-deficient patient who suffered from cardiac and renal malformations in addition to severe neutropenia.

### Case Presentation

A newborn boy (gestational age of 42 weeks) was admitted after birth due to sepsis. Laboratory studies revealed severe neutropenia: white blood cells (WBC) of 2600/ $\mu$ l (9% neutrophils, 90% lymphocytes) with absolute neutrophil count (ANC) of 234/ $\mu$ l, hemoglobin 14.2 g/dl (MCV 105 fl, MCH 32 pg, MCHC 33 g/dl), and platelets 147000/ $\mu$ l. The patient was the first child of healthy consanguineous parents.

The birth weight was 3150 g and head circumference at birth was 33 cm. There was a history of early death of two uncles at the first month of life due to severe infections (Fig. 1). The patient was treated with antibiotics and granulocyte colony-stimulating factor (G-CSF). The neutrophil count increased (WBC 6200/ $\mu$ l, neutrophils 18%, lymphocytes 78%, eosinophils 3%, monocytes 1%, hemoglobin 11.7 g/dl, platelets 666000/ $\mu$ l) and the patient was discharged in good condition after 2 weeks.

Although it was recommended to continue G-CSF therapy, the patient did not receive this treatment after discharge; therefore he experienced several episodes of respiratory infection and diarrhea and he was admitted once again at the age of four months because of diarrhea. Complete blood count indicated severe neutropenia (WBC 5500/ $\mu$ l, neutrophils 8%, lymphocytes 91%, ANC 440/ $\mu$ l) at admission. Bone marrow aspiration revealed marked maturation arrest in myeloid series (at promyelocyte-myelocyte stage), suggesting the diagnosis of SCN. Abdominal sonography revealed moderate hydronephrosis of the left kidney and echocardiography showed atrial septal defect (ASD) and patent ductus arteriosus (PDA). He was treated with lanoxin and captopril in addition to G-CSF therapy. Neutrophil count increased to 1809/ $\mu$ l (WBC 6700/ $\mu$ l, neutrophils 27%, lymphocytes 63%). The patient was discharged in good condition and advised to receive G-CSF regularly.



**Fig. 1:** The pedigree of the patient with G6PC3 syndrome. (Open symbols represent healthy individuals, filled symbols represent affected patients, and symbols with slashes represent deceased individuals. Boxes: males, circles: females)

Therafter he was under regular follow-up and treatment with G-CSF and he did not experience any severe infection leading to hospitalization.

Neutrophil count during follow-up period was above 1500/ $\mu$ l (WBC 9500/ $\mu$ l, neutrophils 55%, lymphocytes 41%, one month after discharge). As of urinary tract infection, diuretic renal scan with TC-99m DTPA showed asymmetrical parenchymal uptake with delayed cortical excretion in the right (immature) kidney. Left kidney showed acceptable initial uptake and cortical excretion, but retention of tracer was prominent in its renal pelvic clearing after lasix injection (hydronephrosis). Further immunological studies were normal: serum IgG 672 (normal range 350-1180) mg/dl, serum IgM 131 (36-104) mg/dl, serum IgA 48 (36-165) mg/dl. Neutrophil count two years after last admission was also above 1500/ $\mu$ l (WBC 5700/ $\mu$ l, neutrophils 36%, lymphocytes 55%).

Although ASD and PDA were documented for this patient, corrective cardiac surgery was not performed, while he is under observation and receives digoxin. He is in good condition now and receives G-CSF regularly and is visited in the outpatient clinic at least twice per year. The latest neutrophil count was 1665/ $\mu$ l (WBC 4500/ $\mu$ l, neutrophils 37%).

Molecular study, recently performed, indicated no somatic mutations in ELA2, HAX1, and CSFR3 genes. A homozygous single base pair (T) insertion was detected (c.935\_936insT/p.Asn313fs). This case was listed as patient no. 11 in a recent survey of G6PC3 syndrome<sup>[11]</sup>.

## Discussion

G6PC3 deficiency is a new identified neutropenic syndrome, which is identified in a group of autosomal recessive SCN patients with additional organ involvement. Twelve patients with the syndrome have been reported until now; among them 10 patients had unusually prominent subcutaneous veins and/or venous angiectasia, 8 had various cardiac malformations, and 5 had urogenital malformations<sup>[11]</sup>. Although the reason of these developmental aberrations is unclear, increased

susceptibility to apoptosis could affect cardiac or urogenital development in these patients<sup>[11]</sup>.

Cardiac and renal malformations were also seen in this reported case.

Maturation arrest in the myeloid differentiation, which is a characteristic finding in SCN patients with mutations in ELA2 and HAX1 genes, is also observed in the patients with G6PC3 mutations. G6PC3 protein is located in the endoplasmic reticulum, which catalyzes dephosphorylation of glucose-6-phosphate.

Deficiency of G6PC3 could lead to an increased endoplasmic reticulum stress and an increased activity of GSK3 $\beta$ , Wnt-signaling, and apoptosis<sup>[12]</sup>.

While mutations of HAX1 gene are believed to be responsible for autosomal recessive form of SCN, mutations of G6PC3 also cause an autosomal recessive neutropenic syndrome. It should be emphasized that more than half of reported patients with G6PC3 deficiency are from the Middle East countries, where consanguineous marriages are common<sup>[13]</sup>.

There are also several patients with SCN from consanguineous families in which the responsible gene is unknown<sup>[4]</sup>.

## Conclusion

Cardiac and urogenital malformations in addition to severe neutropenia could be considered as common manifestations of G6PC3 deficiency. Increasing the knowledge of physicians as well as public education programs is crucial, while prompt and accurate diagnosis of patients with severe congenital neutropenia and administration of appropriate treatments can prevent further complications and improve the quality of life of affected patients.

## References

1. Schaffer AA, Klein C. Genetic heterogeneity in severe congenital neutropenia: how many aberrant pathways can kill a

- neutrophil? *Curr Opin Allergy Clin Immunol.* 2007;7(6):481-94.
2. Wintergerst U, Rosenzweig SD, Abinun M, et al. Phagocytes Defects. In: Rezaei N, Aghamohammadi A, Notarangelo LD, editors. *Primary Immunodeficiency Diseases: Definition, Diagnosis, and Management.* 1<sup>st</sup> ed. Heidelberg: Springer Verlag Berlin; 2008. Pp:131-66.
  3. Boztug K, Welte K, Zeidler C, et al. Congenital neutropenia syndromes. *Immunol Allergy Clin North Am.* 2008; 28(2):259-75.
  4. Rezaei N, Moin M, Pourpak Z, et al. The clinical, immunohematological, and molecular study of Iranian patients with severe congenital neutropenia. *J Clin Immunol.* 2007;27(5):525-33.
  5. Rezaei N, Farhoudi A, Ramyar A, et al. Congenital neutropenia and primary immunodeficiency disorders: a survey of 26 Iranian patients. *J Pediatr Hematol Oncol.* 2005;27(7):351-6.
  6. Rezaei N, Moazzami K, Aghamohammadi A, Klein C. Neutropenia and primary immunodeficiency diseases. *Int Rev Immunol.* 2009; 28(5): 335-66.
  7. Fahimzad A, Chavoshzadeh Z, Abdollahpour H, et al. Necrosis of nasal cartilage due to mucormycosis in a patient with severe congenital neutropenia due to HAX1 deficiency. *J Investig Allergol Clin Immunol.* 2008;18(6):469-72.
  8. Rezaei N, Chavoshzadeh Z, R Alaei O, et al. Association of HAX1 deficiency with neurological disorder. *Neuropediatrics.* 2007;38(5):261-3.
  9. Klein C, Grudzien M, Appaswamy G, et al. HAX1 deficiency causes autosomal recessive severe congenital neutropenia (Kostmann disease). *Nat Genet.* 2007; 39(1):86-92.
  10. Germeshausen M, Grudzien M, Zeidler C, et al. Novel HAX1 mutations in patients with severe congenital neutropenia reveal isoform-dependent genotype-phenotype associations. *Blood.* 2008;111(10):4954-7.
  11. Boztug K, Appaswamy G, Ashikov A, et al. A syndrome with congenital neutropenia and mutations in G6PC3. *N Engl J Med* 2009;360(1):32-43.
  12. Cohen P, Frame S. The renaissance of GSK3. *Nat Rev Mol Cell Biol.* 2001;2(10): 769-76.
  13. Rezaei N, Pourpak Z, Aghamohammadi A, et al. Consanguinity in primary immunodeficiency disorders; the report from Iranian Primary Immunodeficiency Registry. *Am J Reprod Immunol.* 2006; 56(2):145-51.